

Vanishing Brain Lesions An Infequent Presentation : A Case Report

¹Dr Ali Al Mashani, ²Dr Neeraj Salhotra, ³Dr Azmat Ali, ⁴Dr Salim Al Abri, ⁵Dr Mohammad Hashim, ⁶Dr Ahmed al Risi, ⁷Dr. Munthir Al Zabin

¹Sr consultant Dept of Neurosurgery Khoula Hospital Muscat Oman

²Sr Specialist Dept of Neurosurgery Khoula Hospital Muscat Oman

³Specialist Dept of Neurosurgery Khoula Hospital Muscat Oman

⁴Specialist Dept of Neurosurgery Khoula Hospital Muscat Oman

⁵Resident Neurosurgery Dept of Neurosurgery Khoula Hospital Muscat Oman

⁶Medical officer Dept of Neurosurgery Khoula Hospital Muscat Oman

⁷Sr Specialist khoula Hospital Muscat Oman

Abstract: Vanishing brain lesions are infrequently seen condition ¹. Well known in multiple sclerosis , lymphomas with steroids etc ^{2,3}, we herewith report a case of a young female presenting with headache and diplopia and imaging revealed cavernous sinus lesion .Surgery was attempted but due to vigorous venous channels was abandoned . However post of imaging revealed vanishing lesion ans patient completely improved .

Keywords: vanishing intracranial lesions .

1. INTRODUCTION

Vanishing intracranial lesions are seen frequently in neurological conditions like multiple sclerosis who are know to wax and wane² . Many times glioblastomas and lymphomas are also known to disappear with steroids⁵ .White matter lesions neurologists see many times vanishing in their course of treatment .Or case is a cavernous sinus lesion presenting with headache and diplopia and vanished spontaneously after a failed surgical excision attempt ,

2. MATERIALS AND METHODS

A young female 20 yr old was admitted in our hospital with complaints of headache and double vision for last 1 month . On examination patient was fully conscious but had diplopia with right 3 rd and 6 th nerve involvement . No other deficit was seen vision was normal . Patient underwent CT brain which revealed a lesion with contrast enhancement in cavernous sinus Fig 1 &2 . Patient underwent a MRI brain which further revealed well defined contrast enhancing cavernous and paracavernous sinus lesion of mixed intensity Fig 3,4&5.Patient was offered surgery to establish the histopathological diagnosis . All possible risks and complications were explained .

3. RESULTS

After family agreed patient underwent right pterional craniotomy and attempted excision of the lesion . Intraoperatively however prominent venous channels were noted and made entry to the cavernous sinus difficult . After repeated attempts failed with local coagulation procedure was abandoned and wound was closed and patient extubated and sent back to the ward . Postop CT brain done next day was satisfactory and patient was discharged home with adviceto come after 6 weeks with new MRI .

Patient when reported to out patient department after 12 weeks was totally asymptomatic , with headache and diplopia gone and MRI revealing disappearance of the cavernous sinus lesion Fig 8. Patient was again followed up after 12 months with another MRI and patient was still asymptomatic and there was no recurrence of the lesion Fig 9.

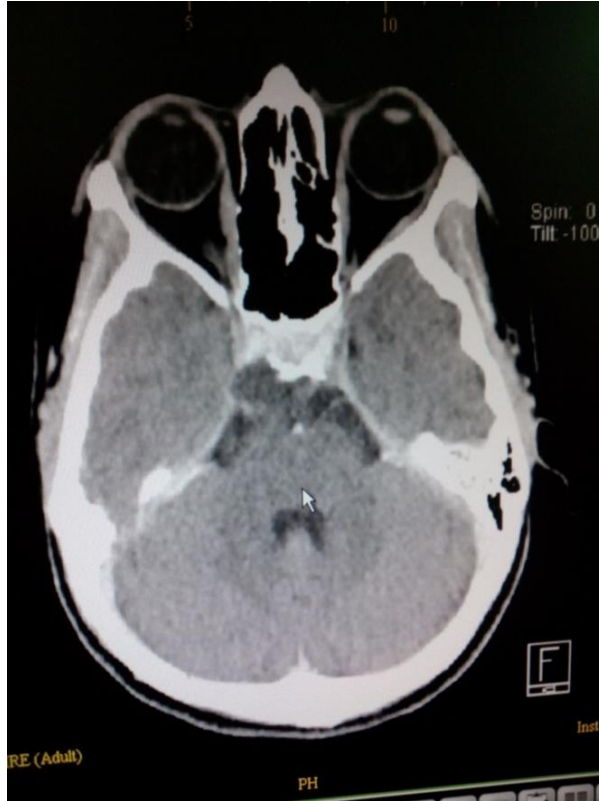

Fig 1 Plain CT brain of the patient showing cavernous paracavernous lesion eroding clivus

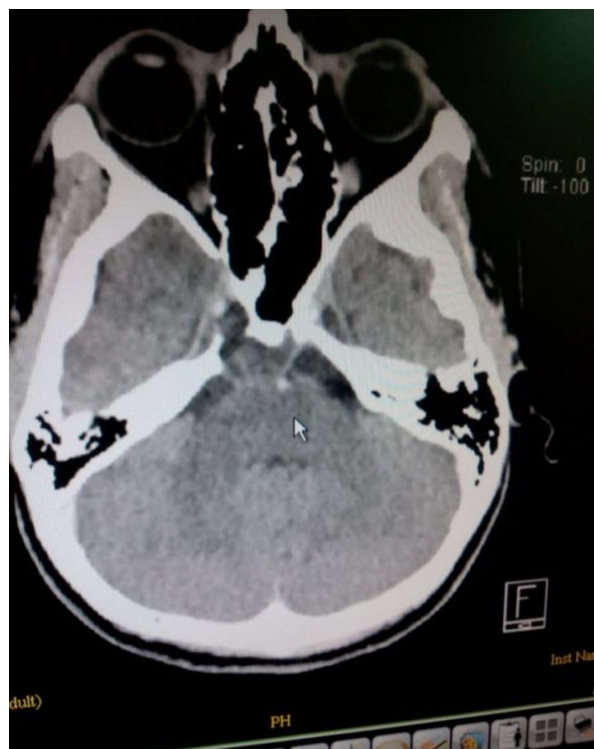

Fig 2 Pre op CT brain revealing the cavernous paracavernous lesion

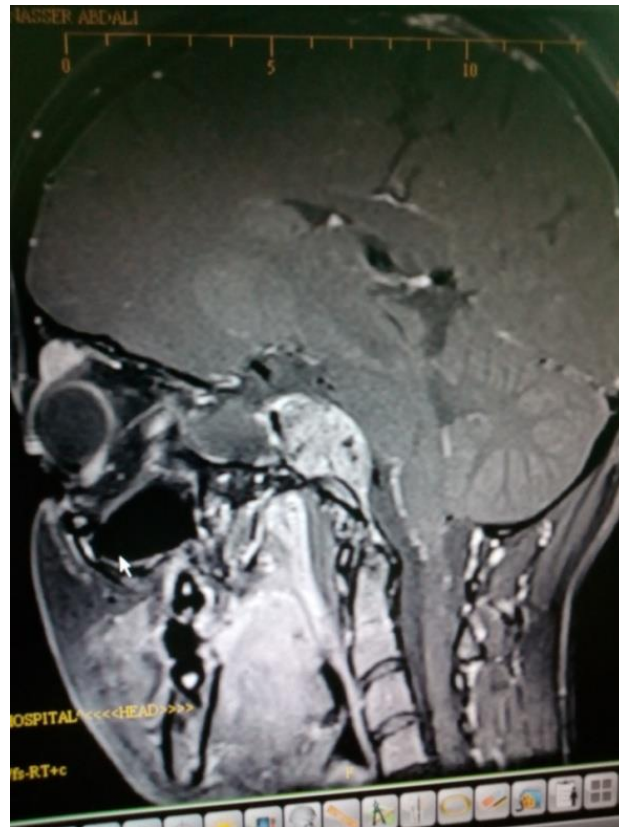


Fig 3 Pre op Sagittal MRI with contrast showing the lesion

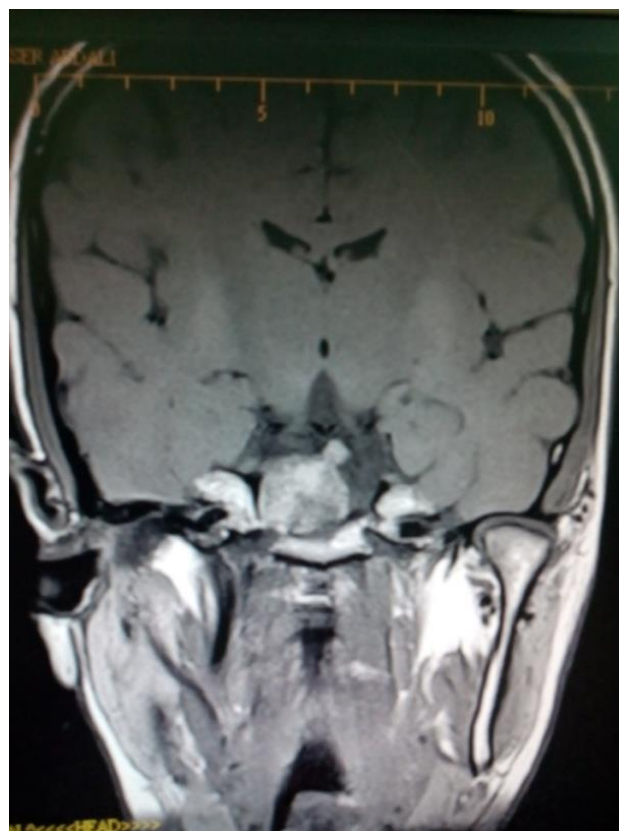


Fig 4 Pre op coronal view of the lesion .

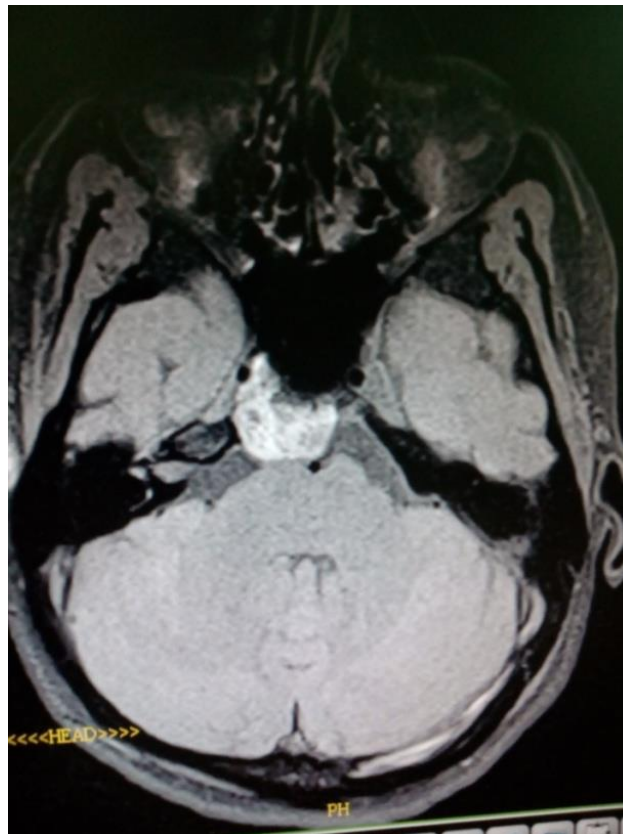


Fig 5 Pre op axial MRI contrast showing the lesion

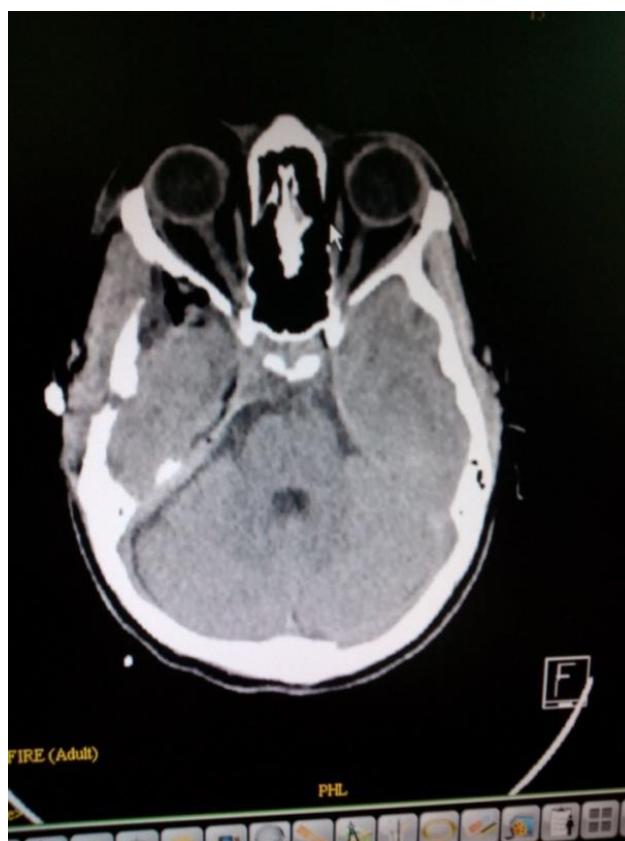

Fig 6 Immediate post op CT brain

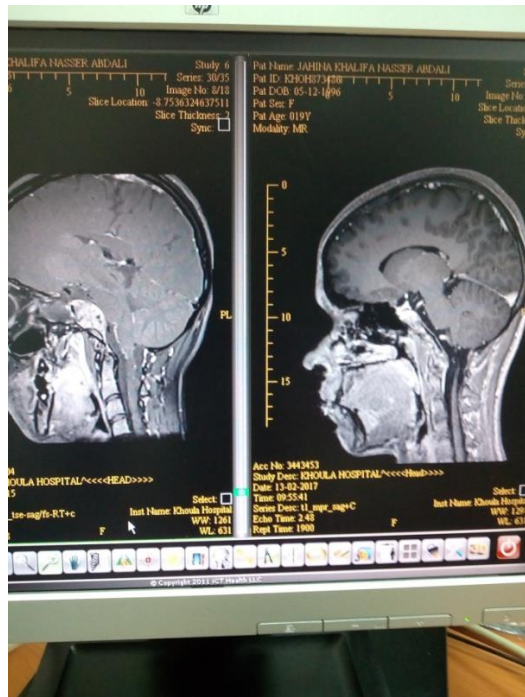

Fig 7 Pre and post op MRI after 2 yrs

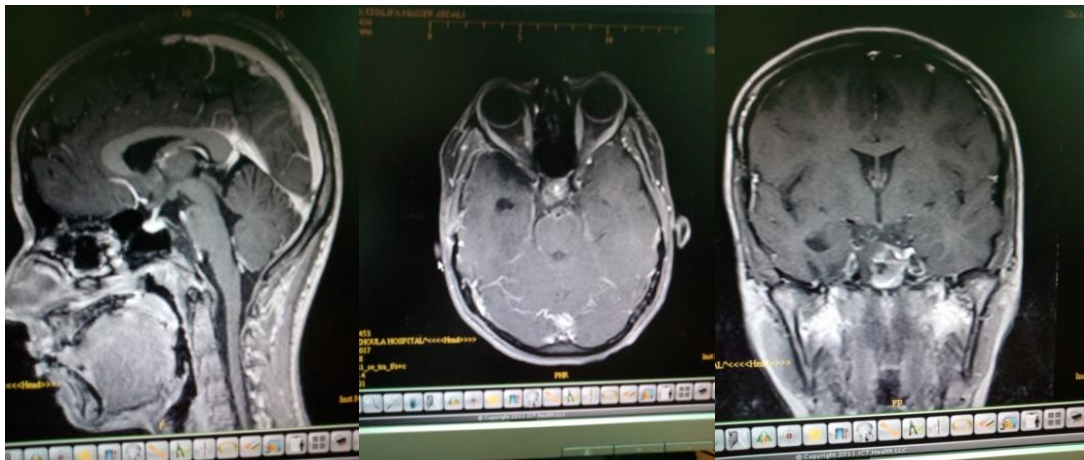


Fig 8 Post op MRI in 2016

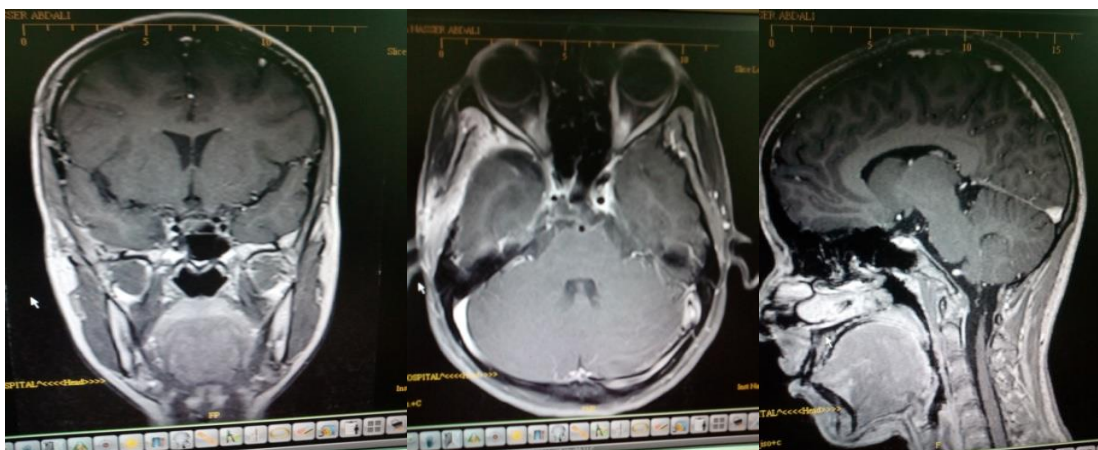


Fig 9 Post op MRI in 2017

4. DISCUSSION

As we review the literature in 2015 Mottagno PP et al reported vanishing tumours in the pineal region and described them as ghost tumours ? . They blamed surgical manipulation causing ischemic changes in the tumour leading to its disappearance or a apoplexy in the lesion which spontaneously regressed over a period of time .¹ In 2015 Herwerth M et al described differential diagnosis of white matter vanishing lesions in the back ground of multiple sclerosis .² In 2006 Ayrygnac X et al also described multiple sclerosis presenting as vanishing lesions and importance of careful MRI sequences study to differentiate them .In 2013 Bugiani M blamed hyalurraonanaccumulation and arrested oligodendrocyte pregenitor maturation for the vanishing lesions seen in multiple sclerosis .⁴ In 2009 Goh JJ described cases of glioblastoma disappearing after corticostriod therapy .⁵ In 2016 Patriarca L et al also described pineal regions spontaneously regressing without any intervention in follow up MRI⁶. In 2012 Okita Y stressed the need of 5 yr follow up in these disappearing lesions as chances of malignancy say lymphoma are high and should be carefully excluded .

5. CONCLUSION

Our case is also one of the cases reported in literature where we don't have any histopathology but as attempted surgical removal with perilesional blood supply coagulation could be reason for gradual disappearance of the lesion . However patient will be followed for 5 yrs to finally label it as vanishing lesion .

REFERENCES

- [1] World Neurosurg. 2016 Apr;88:64-9. doi: 10.1016/j.wneu.2015.12.080. Epub 2015 Dec 31.Spontaneous Regression of Pineal Lesions: Ghost Tumor or Pineal Apoplexy? Mottagno PP, Frassanito P, Massimi L, Tamburrini G, Novello M, Lauriola L, Caldarelli M
- [2] Adult-onset vanishing white matter disease as differential diagnosis of primary progressive multiple sclerosis: a case report.Herwerth M, Schwaiger BJ, Kreiser K, Hemmer B, Ilg R. Mult Scler. 2015 Apr;21(5):666-8. doi: 10.1177/1352458514546515.
- [3] Eur J Neurol. 2016 Jun;23(6):995-1000. doi: 10.1111/ene.12931. Epub 2016 Jan 4.Brain magnetic resonance imaging helps to differentiate atypical multiple sclerosis with cavitorylesions and vanishing white matter disease.Ayrygnac X, Menjot de Champfleure N, Menjot de Champfleure S, Carra-Dallièrre C, Deverdun J, Corlobe A, Labauge P.
- [4] Hyaluronan accumulation and arrested oligodendrocyte progenitor maturation in vanishing white matter disease.Bugiani M, Postma N, Polder E, Dieleman N, Scheffer PG, Sim FJ, van der Knaap MS, Boor I.Brain. 2013 Jan;136(Pt 1):209-22. doi: 10.1093/brain/aws320
- [5] Vanishing glioblastoma after corticosteroid therapy.Goh JJ, See SJ, Ang E, Ng WH. J Clin Neurosci. 2009 Sep;16(9):1226-8. doi: 10.1016/j.jocn.2008.10.029
- [6] Neuroradiol J. 2016 Oct;29(5):303-6. doi: 10.1177/1971400916655480. Epub 2016 Jun 14.Vanishing pineal mass in a young patient without therapy: Case report and review of the literature.Patriarca L, D'Orazio F, Di Cesare E, Splendiani A.
- [7] Clin Neurol Neurosurg. 2012 Nov;114(9):1217-21. doi: 10.1016/j.clineuro.2012.02.053. Epub 2012 Mar 22.Long-term follow-up of vanishing tumors in the brain: how should a lesion mimicking primary CNS lymphoma be managed? Okita Y, Narita Y, Miyakita Y, Ohno M, Fukushima S, Maeshima A, Kayama T, Shibui S